

Fickes Holistic Care Corp

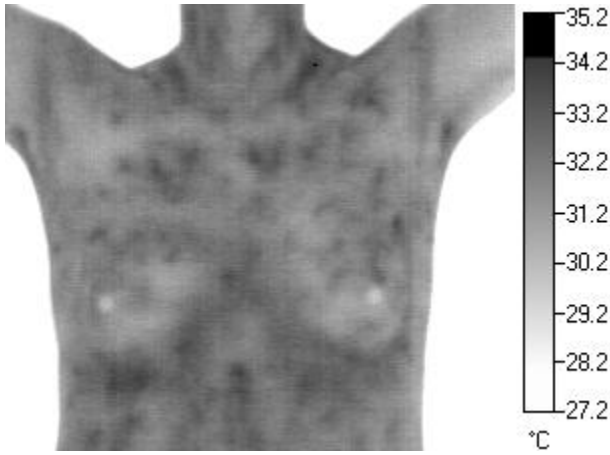
Dr. Linda Fickes, D.C., Board Certified Medical Thermographer, Board Certified Clinical Nutritionist
824 Hahaione St.,
Honolulu, Hawaii 96821 USA
Phone: 808 395-6800 Fax: 808 396-0919
Celiac Presentation with Thermal Imaging

Type Of Exam: Full Body
Female, age 55

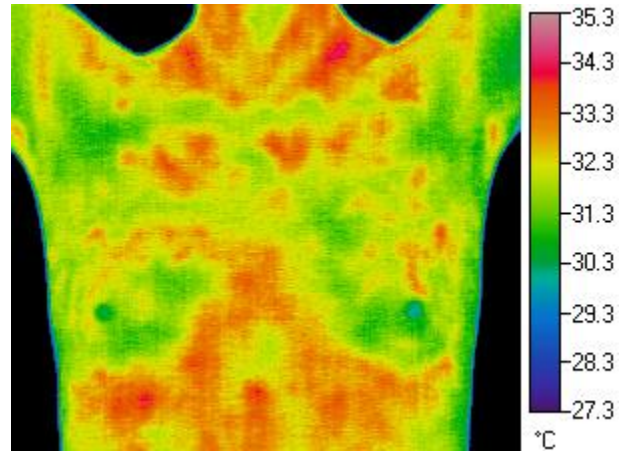
Date of Exam: November 05, 2010
Reported By: Dr. Linda Fickes, D.C.

Thermographic Findings: Hot blotchy lymphatic inflammation throughout the trunk is apparent, indicating immune system irritation, common with gluten sensitivity. These heat patterns emanates from the severe inflammation in the small intestine, colon, liver and gallbladder, seen below, typically damaged by gluten.

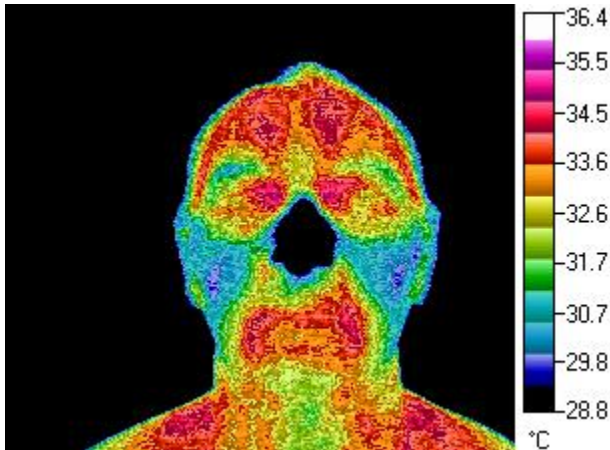
Ant. Breast



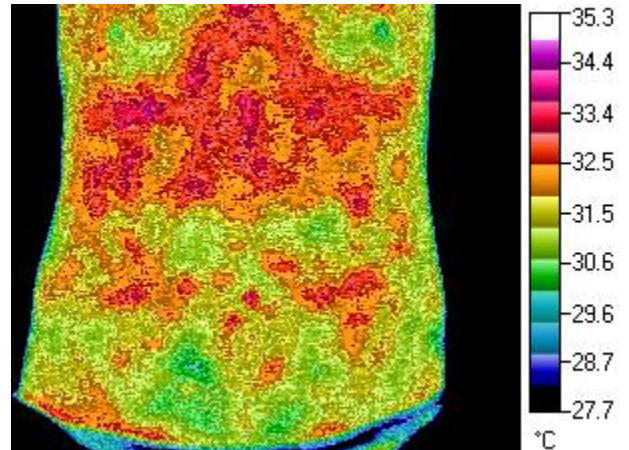
Ant. Breast



Ant. Cranial Facial



Ant. Lower Torso



The forehead heat pattern indicates diminished blood flow to the brain, another common sequela of gluten sensitivity. Thyroid is colder and more inactive than optimal. Thyroid is a common place for auto-immune attack with gluten sensitivity.